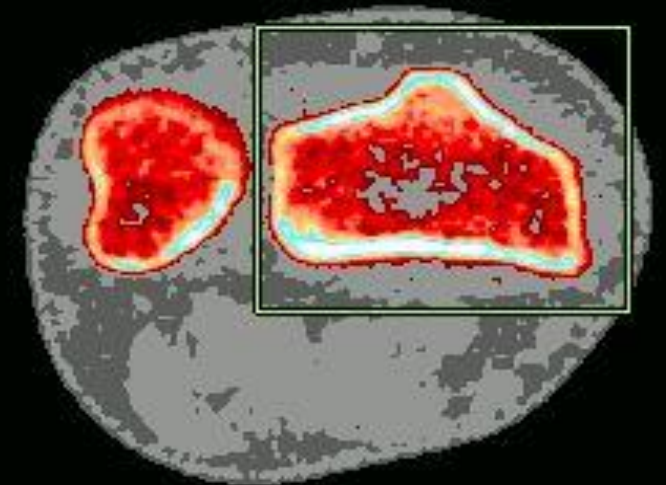
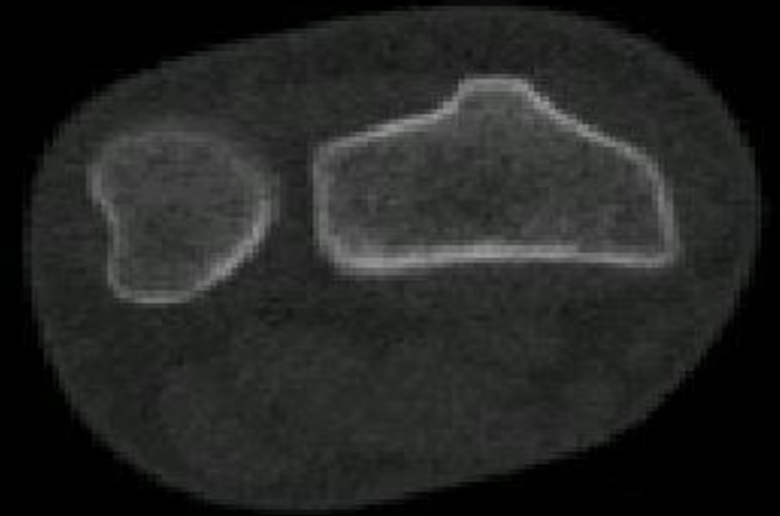


How to perform forearm pQCT

Dr Mícheál O'Beasail

Overview

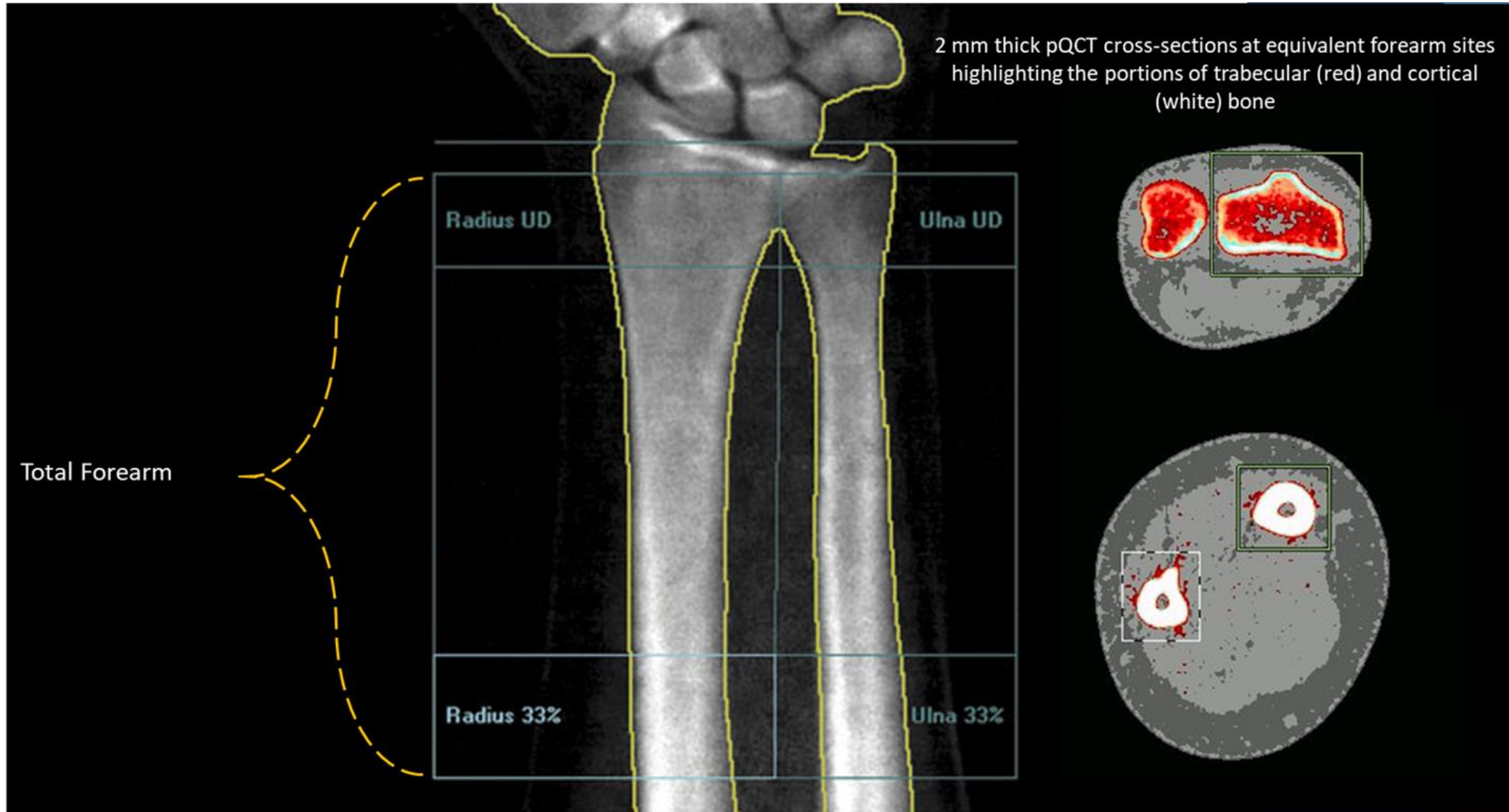
- Background
- Forearm length measurement
- Scout views
 - Adults
 - Children
- Scan sites & outcomes measures
- Scan grading
- Common mistakes



Why measure the forearm?

- Fractures of the distal radius are relatively common
 - 25% of paediatric fractures (Nellans et al. 2012)
 - 18% of fractures in the elderly (Nellans et al. 2012)
- It is a non-loading site
 - Why might this be of interest?
 - Less confounded by weight
 - Less confounded by changing weight

How does this relate to forearm DXA?



Forearm length measurement


- Non-dominant arm unless impracticable
 - Injury to limb
 - Immobilisation of limb
 - Metal implants
- Arm bent at a right angle
- Distance measured is from the olecranon to the distal edge of the ulnar styloid process
- Measured with a metal ruler to the nearest 0.5 mm
- **NB only measure adults at visit 1 – you may not get the same length twice**

Participant positioning

Tips

- **NB If your participant is comfortable they will move less!**
- If necessary we can raise or lower the scanner height
- Be mindful of elbows and shoulders
- If the chair has wheels – apply the brakes

Scout views

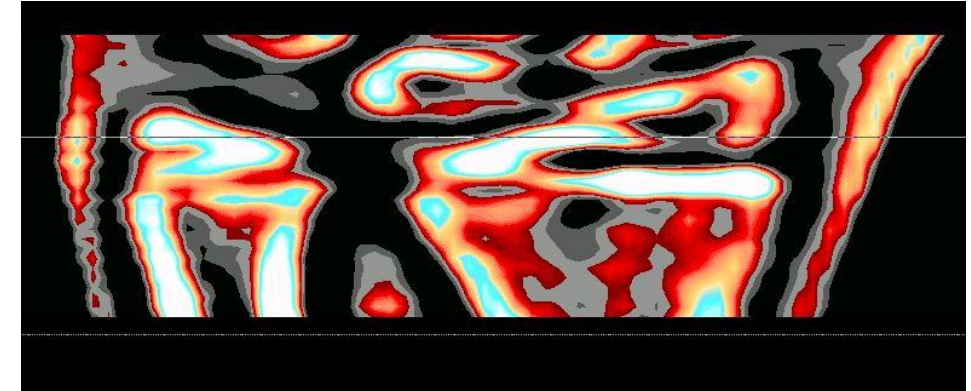
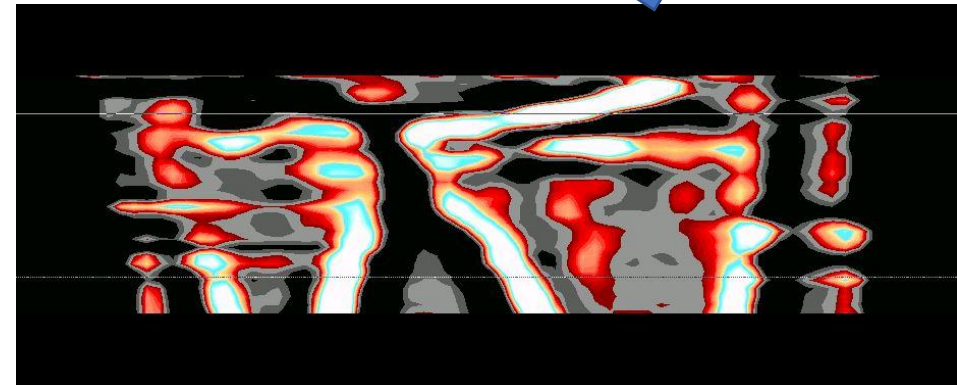

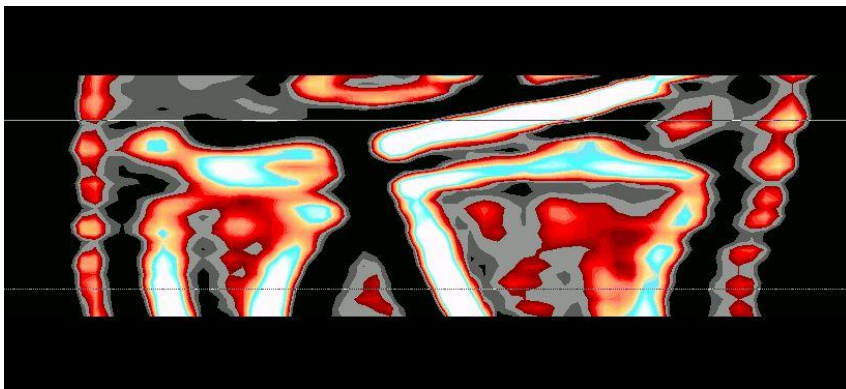


Quick refresher...

- What's wrong each tibia scan?
 - (a)
 - (b)
 - (c)

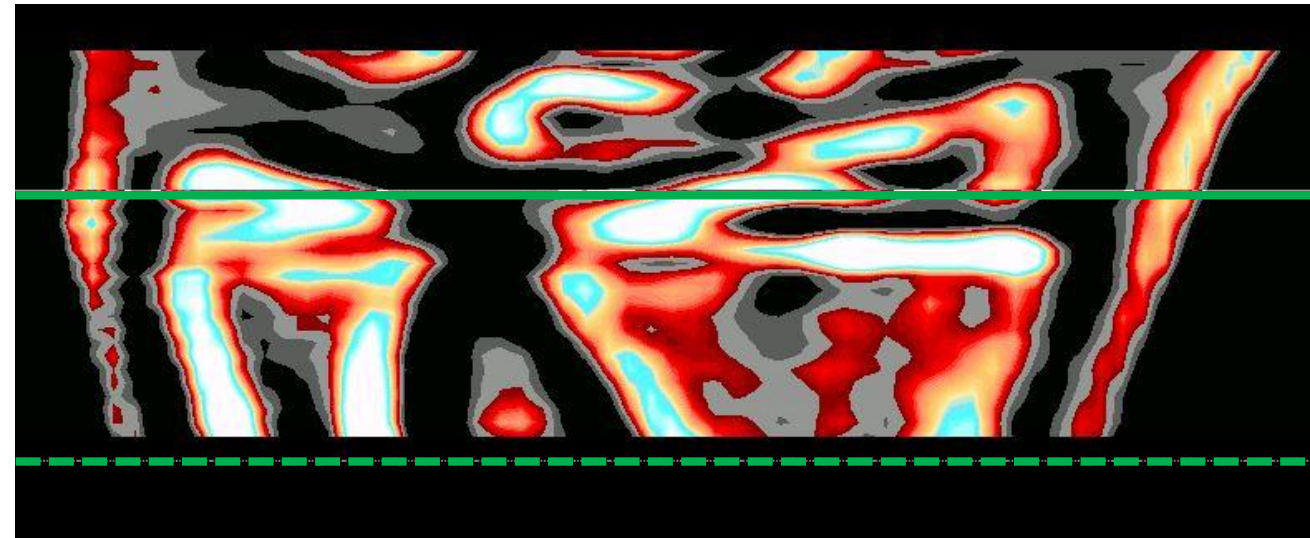
Children = growth plate

- For children we always use the growth plate for our reference line – why?



What about adolescents??

- When should we move from the growth plate to the endplate
- If the growth plate <50% resorbed into the endplate – use growth plate
- If the growth plate >50% resorbed into the endplate – use endplate



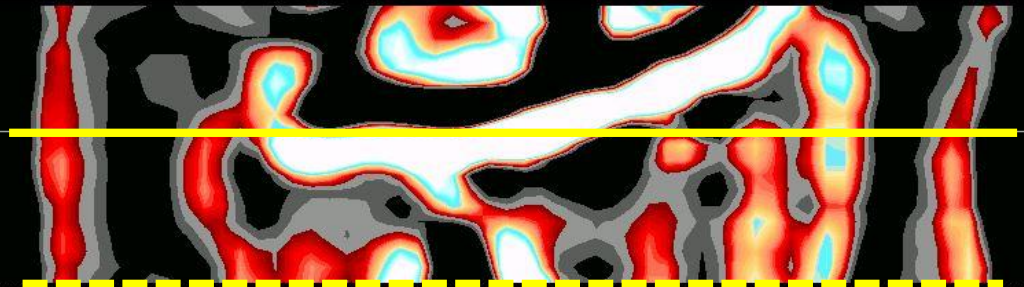

Adults = endplate

- Scout view should run along the flattest part of the radius endplate
- Be careful as sometimes the endplate can be angled
- If there is movement on the scout or you are unsure where the reference line should go consider rescanning

reference line

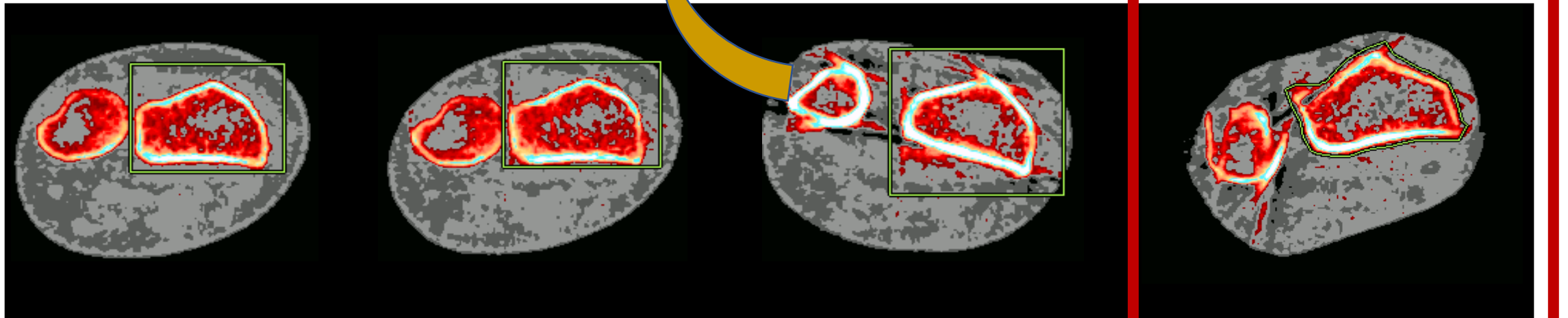
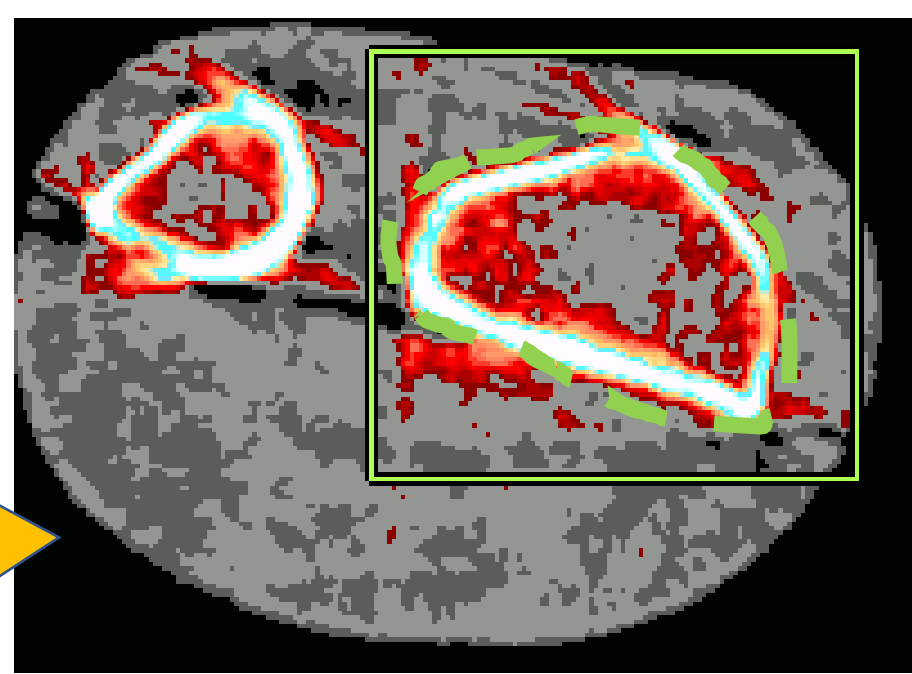


measurement line



Scan grading

- Scan grades 0, 1, 2 & 3
- Which would you exclude?
- Is there anything you could do to improve the data you get from this scan?



1

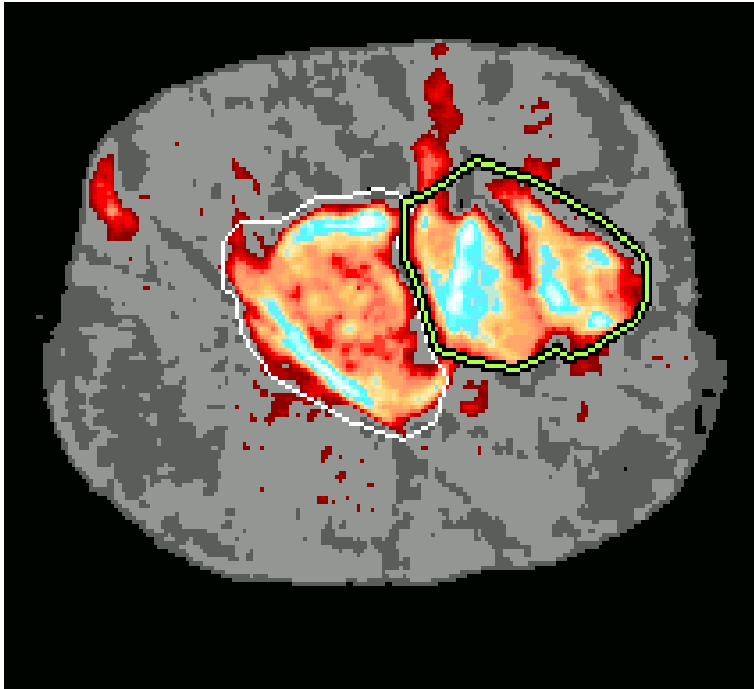
2

3

4

exclude

Common mistakes



What's wrong with this scan?

Q: Is there any other reason you might see a scan like this?

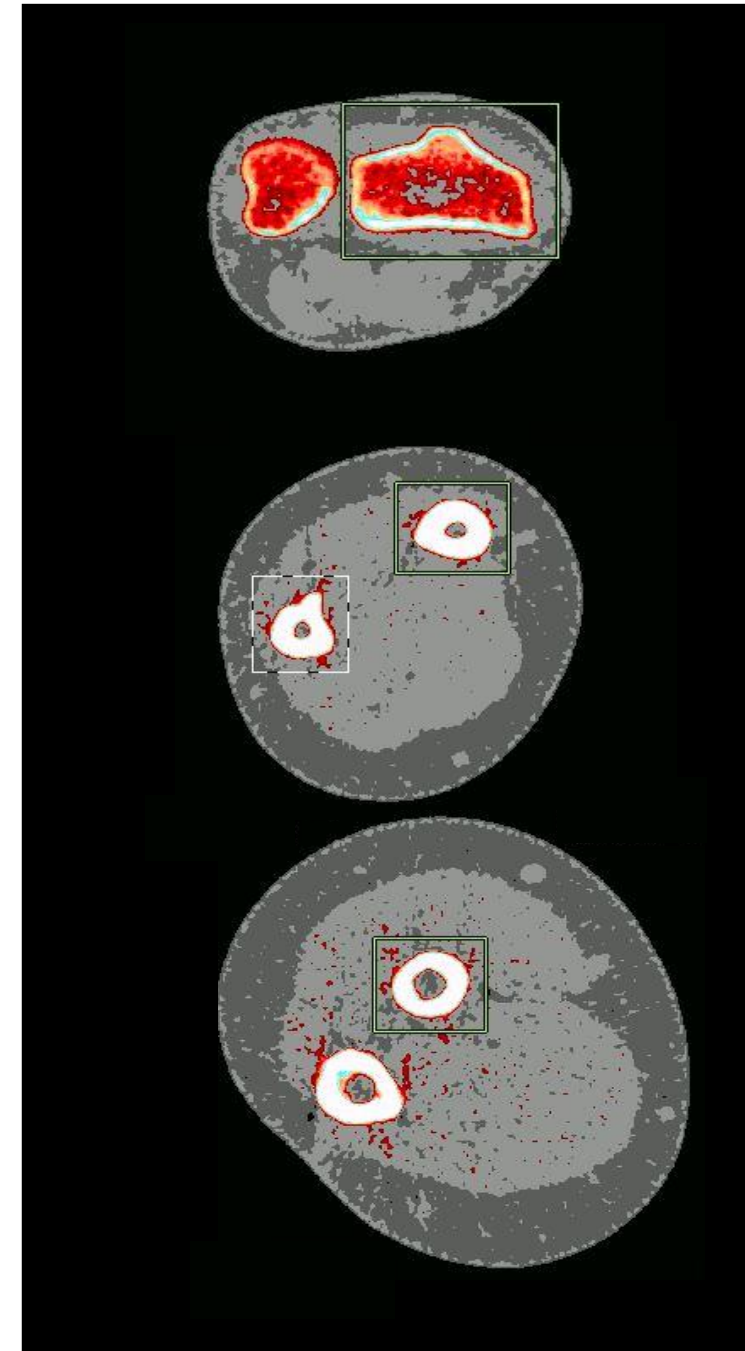
A: Object length entered incorrectly (e.g. 30 mm vs 300 mm)

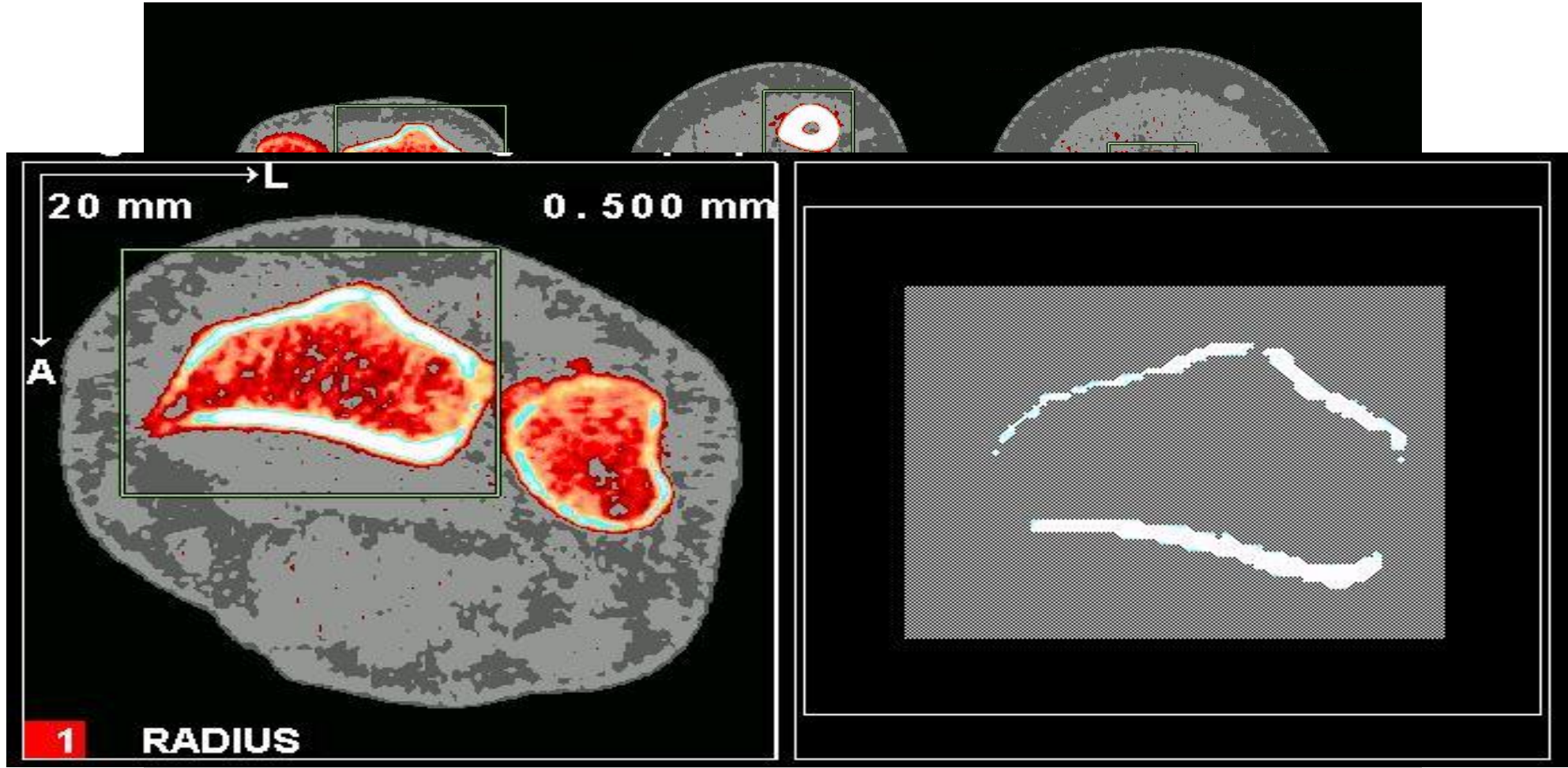
Other potential issues?

- Excessive movement on SV
- Extending SV
- Stopping an SV early
- Growth arrest lines...

Now you have your scans...

- What are you going to look at?
- Bone mineral density
- Bone geometry
- Bone strength
- Bone microarchitecture
- Mineral distribution
- Fat area
- Muscle density





Endosteal circumference

Periosteal circumference

Endosteal circumference

Periosteal circumference

Muscle CSA

Fat CSA

Muscle Density

Body composition measures

Questions?